

Congenital nuclear cataract

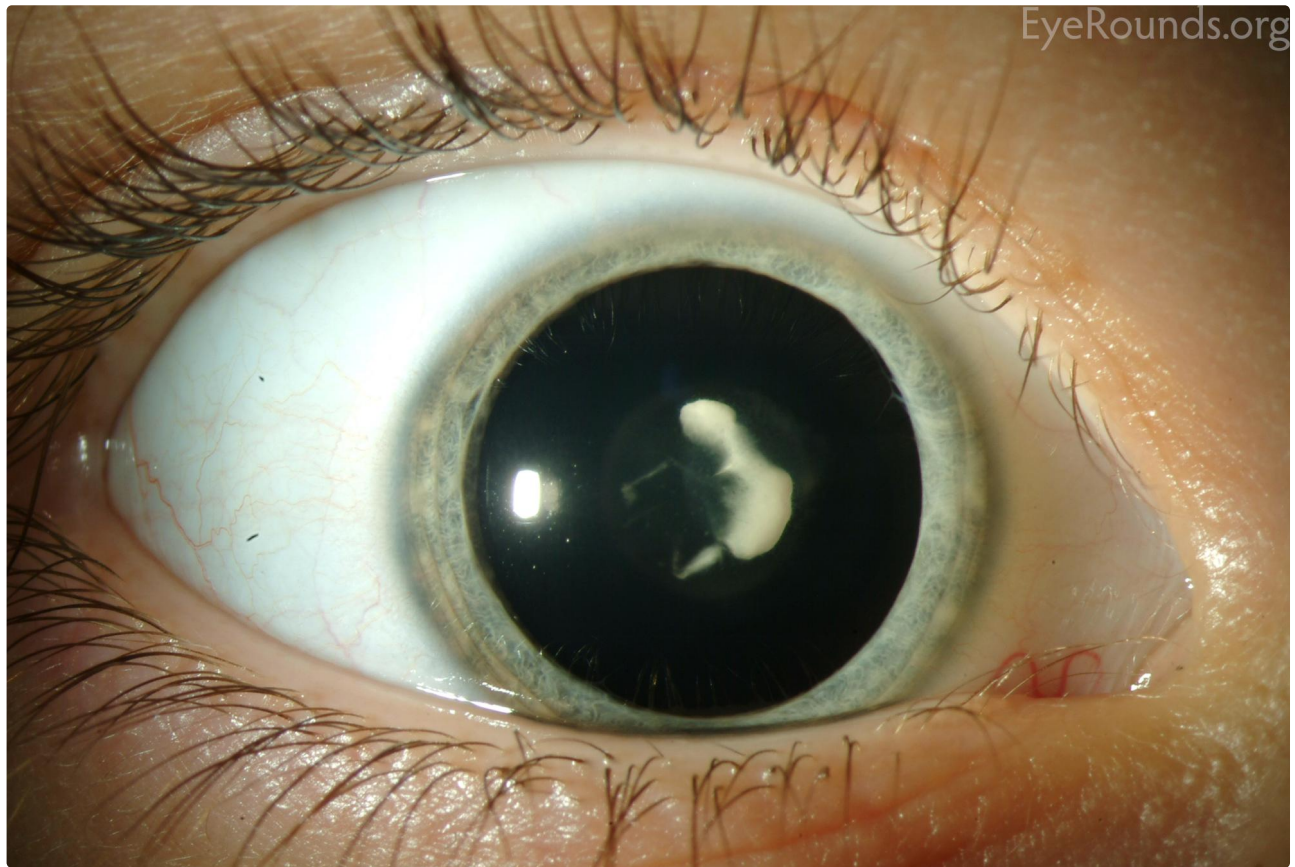
Category(ies): [Cataract](#), [Lens](#), [Pediatrics](#)

Contributor: [Jesse Vislisel, MD](#)

Photographer: [Toni Venckus, CRA](#)



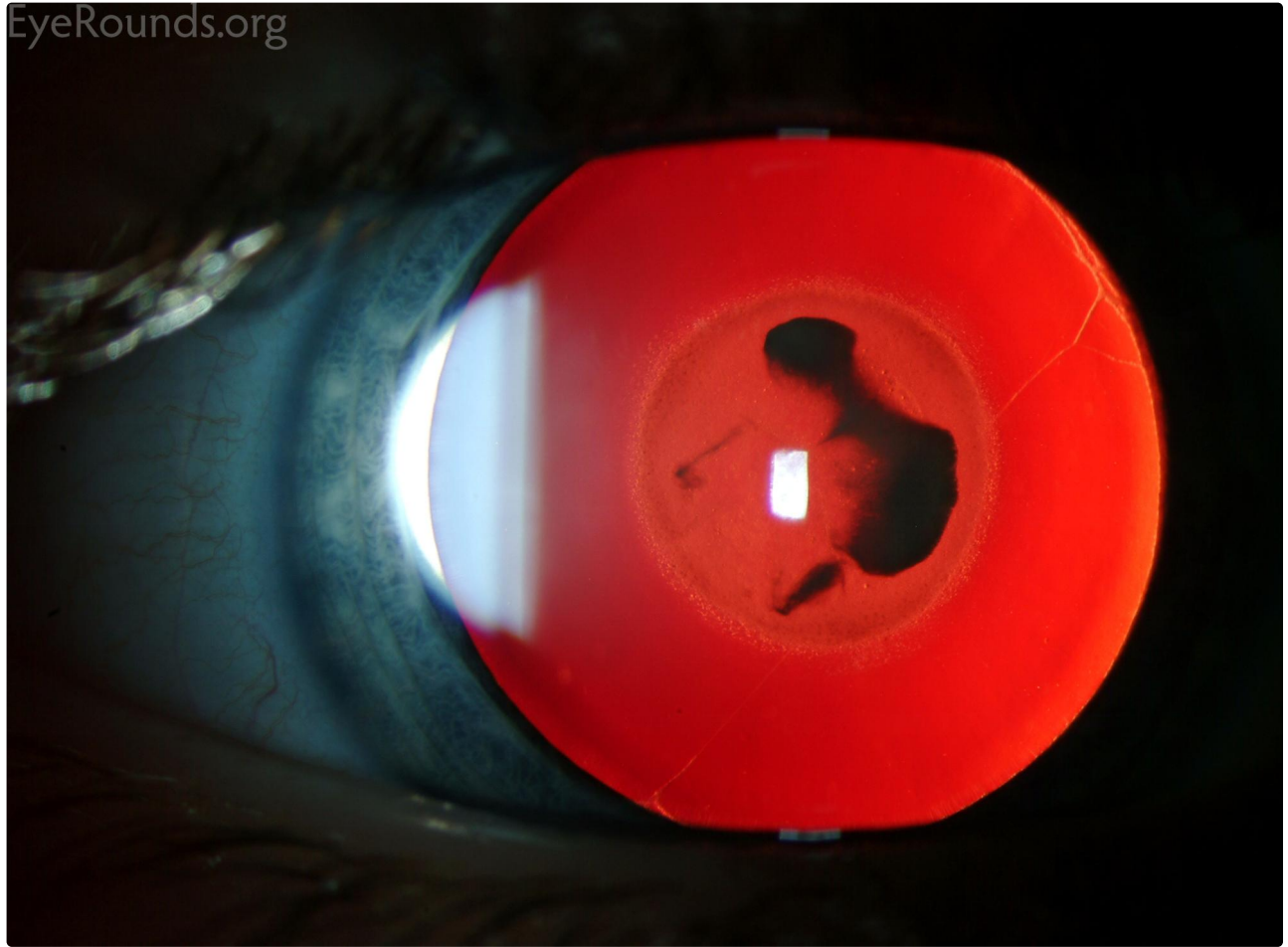
Congenital nuclear cataracts may involve the entire nucleus, or a portion of it as seen in this photograph. These photographs also show a mild persistent pupillary membrane which is most visible in the red reflex.



[Enlarge](#)

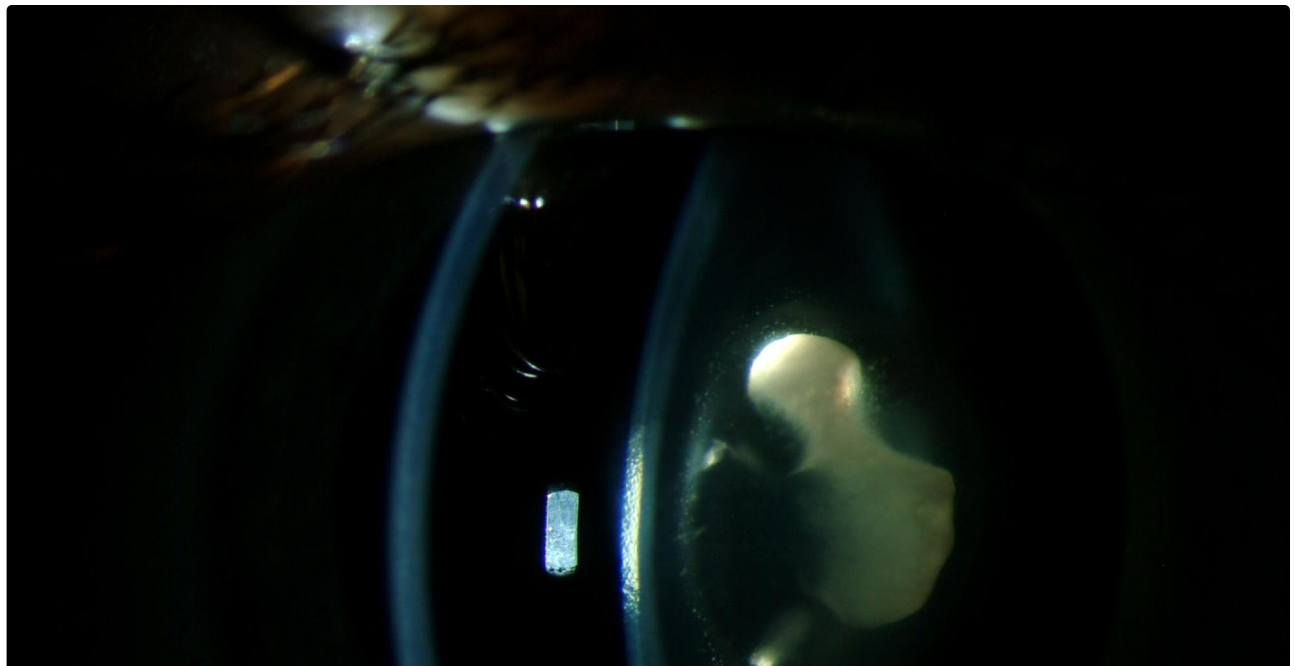
[Download](#)


EyeRounds.org



[Enlarge](#)

[Download](#)





[Enlarge](#) [Download](#)

Image Permissions:



Ophthalmic Atlas Images by [EyeRounds.org](#), [The University of Iowa](#) are licensed under a [Creative Commons Attribution-NonCommercial-NoDerivs 3.0 Unported License](#).

Address

University of Iowa
Roy J. and Lucille A. Carver College
of Medicine
Department of Ophthalmology and
Visual Sciences
200 Hawkins Drive
Iowa City, IA 52242

[Support Us](#)

Legal

Copyright © 2019 The University of
Iowa. All Rights Reserved
[Report an issue with this page](#)
[Web Privacy Policy](#) |
[Nondiscrimination Statement](#)

Related Links

[Cataract Surgery for Greenhorns](#)
[EyeTransillumination](#)
[Gonioscopy.org](#)
[Iowa Glaucoma Curriculum](#)
[Iowa Wet Lab](#)
[Patient Information](#)
[Stone Rounds](#)
[The Best Hits Bookshelf](#)

EyeRounds Social Media

Follow



Receive notification of new cases,
[sign up here](#)
[Contact Us](#)
[Submit a Suggestion](#)